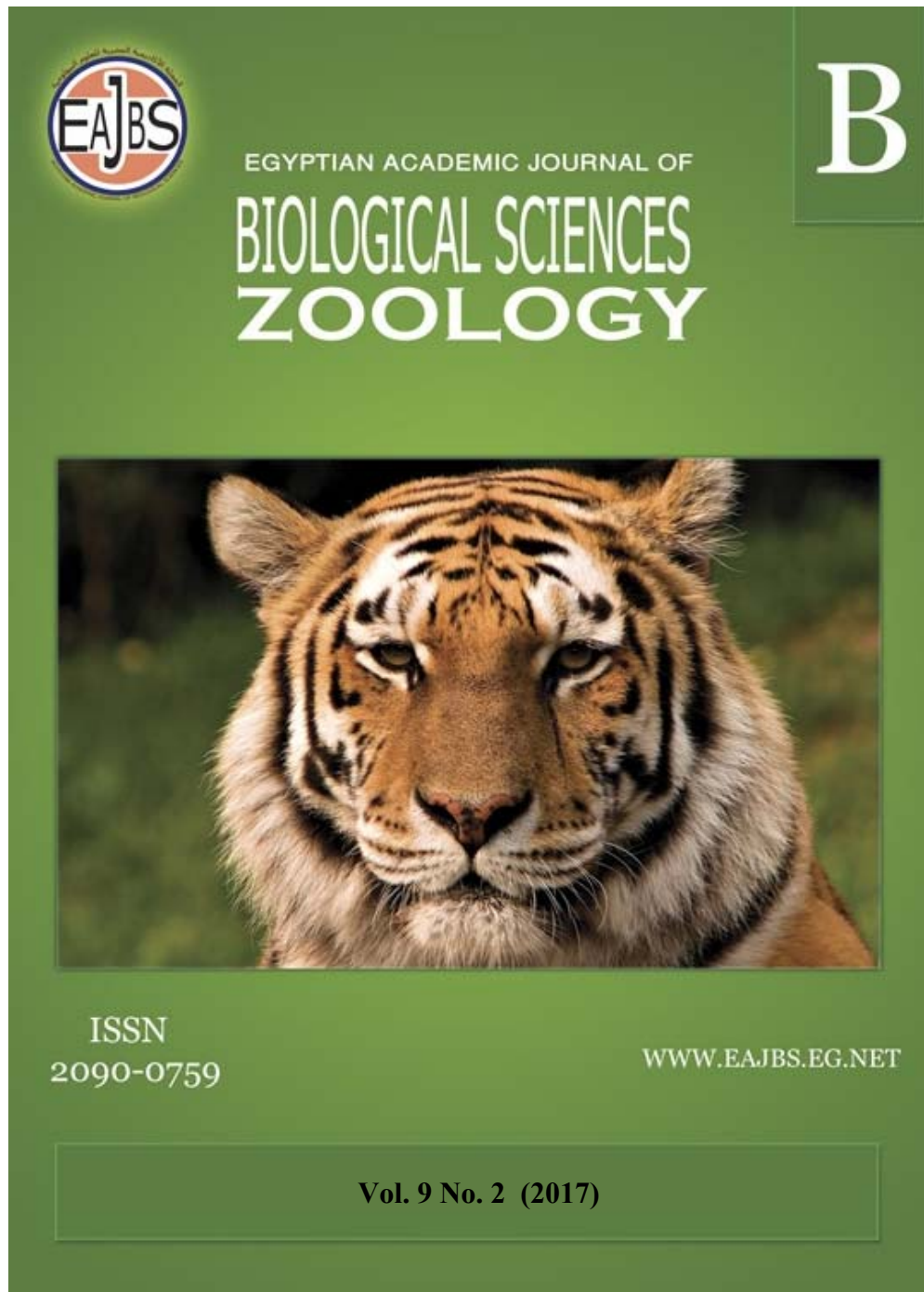



**Provided for non-commercial research and education use.
Not for reproduction, distribution or commercial use.**



Egyptian Academic Journal of Biological Sciences is the official English language journal of the Egyptian Society of Biological Sciences, Department of Entomology, Faculty of Sciences Ain Shams University.

The Journal publishes original research papers and reviews from any zoological discipline or from directly allied fields in ecology, behavioral biology, physiology & biochemistry.

www.eajbs.eg.net



Ameliorative effects of *Nigella sativa* and vitamin E on the toxicity induced by liver extract of *Lagocephalus spadiceus* in male Albino rats

**Muhammad M. A. Salman¹; Naglaa R. A. Kasem¹; Shaymaa D. Sh. Mohareb¹
and Atef M. Khalil²**

1-Zoo Department, Faculty of Science; South Valley University, Qena

2-Pathology and Clinical Pathology Department, Faculty of Veterinary Med.,
South Valley University, Qena

E.Mail : awnak_55@yahoo.com

ARTICLE INFO

Article History

Received:2/9/2017

Accepted: 26/10/2017

Keywords:

Lagocephalus spadiceus,
Tetradotoxin(TTX), *Nigella*
sativa, vitamin E.

ABSTRACT

This study was aimed to investigate the curative effect of some antioxidants such as *Nigella sativa* seeds and vitamin E on hematological, biochemical disorder and histopathological alteration induced by liver extract of puffer fish *Lagocephalus spadiceus* in male Albino rats. Five groups of adult male Albino rats were established (n= 10). Group 1: rats were administered normal saline for 10 days and served as normal group (1 ml / 100gm per b. w. intraperitoneally for 10 days. Group 2: rats were injected intraperitoneally daily, for 10 days, with *L. spadiceus* liver extract and served as control group (1ml/100gm per b. w.). Group 3: rats were oral administration of *Nigella sativa* extract for 30 days after daily injected, with *L. spadiceus* liver extract for 10 days. Group 4: rats were oral administration of vitamin E daily for 30 days after daily injected with *L. spadiceus* liver extract for 10 days. Group 5: rats were daily oral administration of *Nigella sativa* extract + vitamin E for 30 days after daily injected with *L. spadiceus* liver extract for 10 days. In the control group (gp. 2) hematotoxicity was determined by significant decrease in red blood cells (RBCs), haemoglobin (Hb) and PCV value, with marked elevation in white blood cells (WBCs) and blood Platelets (PLTs), as well as there are an elevation in serum ALT, AST, ALP, creatinine, urea and uric acid associated with reduction in albumin and Total protein. In addition to, degenerative and necrotic changes showed in liver and kidneys.

It could be concluded that *Nigella sativa* and vitamin E, clarified a modulatory role against the cellular damage produced by free radicals induced by *L. spadiceus* liver extract.

INTRODUCTION

Tetradotoxin (TTX), one of the most powerful neurotoxins known, it is about 1200 times more toxic to humans than cyanide and it has no known antidote. This toxin binds to the sodium channels of the excitable tissues in the human body (muscles and nerves) and the inhibition of sodium ions through the channels effectively immobilises these tissues (Luo *et al.*, 2012).

Pufferfish (Tetraodontidae family) is the best known source of TTX (Noguchi and Arakawa, 2008 and Bane *et al.*, 2014). TTX is not produced by puffer fish itself, but most likely originates from a symbiosis of bacteria with marine animals (Lago *et al.*, 2015). Besides puffer fish, other species known to harbour TTX include: gastropods (Luo *et al.*, 2012), newts (Mebs *et al.*, 2012), crabs (Lin *et al.*, 2012), frogs (Pires *et al.*, 2003), sea slugs (McNabb *et al.*, 2010 and Wood *et al.*, 2012), star fishes (Lin and Hwang, 2001) blue-ringed octopuses (Williams and Caldwell, 2009 and Williams *et al.*, 2012), ribbon worms (Asakawa *et al.*, 2000) and bacteria (Yang *et al.*, 2010).

The amount of TTX accumulated in pufferfish depends on the species and varies among organs in different seasons but it is concentrated mainly in ovary, liver, and other body parts, as the intestine (Yu *et al.*, 2011).

TTX acts by blockage of the sodium channels and reduces the membrane excitability of vital tissues, of the heart myocytes, skeletal muscles, and the central and peripheral nervous systems resulting in the occurrence of typical symptoms and even death in the most severe cases (Hwang and Noguchi, 2007).

The severity of the symptoms induced by the TTX is dose dependent (Homaira *et al.*, 2010). The symptoms included tingling of the tongue and lips, headache, vomiting, muscle weakness, ataxia and even death due to respiratory and/or heart failure. Also TTX is responsible for 30–50 cases of intoxications occurred every year (Van Apeldoorn *et al.*, 2007).

Herbal medicines derived from plant extracts are being increasingly utilized to treat a wide variety of clinical diseases, with relatively little knowledge regarding their modes of action. There is no doubt that herbal products chemically defined component that can protect the liver from various injuries (Negi *et al.*, 2007).

Nigella sativa (*N. sativa*), which is an annual plant that belongs to the Ranunculaceae family, is widely grown in many countries (Khazdair, 2015 and Gholamnezhad *et al.*, 2016). The chemical compounds that make up black seed vary, but its major components are alkaloids, as well as fixed and volatile oils. The fixed oils include linoleic acid, oleic acid and palmitic acid.

Thymoquinone, a volatile oil, is the most active constituent of *N. sativa* (Al-Saleh *et al.*, 2006). Black seed has many medicinal properties, including neuroprotective (Saleem *et al.* 2012), hepatoprotective (Pourbakhsh *et al.*, 2014), hypotensive and antidiabetic (Khan and Afzal, 2016), renal protective (Dollah *et al.*, 2013), bronchodilatory, antibacterial and anti-tumor (Gholamnezhad *et al.*, 2016), anti-inflammatory (Boskabady *et al.*, 2011) and immunomodulative (Gholamnezhad *et al.*, 2015) properties.

Vitamin E (tocopherol) is the major lipid-soluble antioxidant, present in all cell membranes, which protects cells against lipid peroxidation (Pal *et al.*, 2014). Also, it is well known that vitamin E is a free radical scavenger, i.e., sacrificial molecule with which the proxy radicals preferentially react, rather than with biological molecules, thus preventing damage to cell structures (Niki, 2014).

MATERIALS AND METHODS

Experimental animals:

Fifty adult male Wister Albino rats of approximate age and weight (6-8 weeks) (weighing 200 ± 10 g) were obtained from the laboratory animal house, Assuit University, Egypt. All animals were housed in clean cages and given standard diet and clean water ad libitum. Cages were placed in an air-conditioned room ($23 \pm 3^\circ\text{C}$) with 12:12 hour light: dark cycle. Animals were kept for two weeks before starting of

the experiment for acclimatization, during which they subjected for clinical and laboratory examinations. The experimental protocol was approved by the experimental animal ethics committee, Faculty of Science, South Valley University, Qena, Egypt.

Collection of *Lagocephalus spadiceus* (*L. spadiceus*) fish and Preparation Fish extract:

Specimens of puffer fish *L. spadiceus* were collected from local fishermen who usually catch the fish using trawl net from suez coast. Samples were frozen at -20 ° C until use. The toxin extraction in brief: 10 g of liver was carefully dissected from *L. spadiceus* and minced properly. To this minced tissue 2.5 volumes of 0.1% acetic acid was added and boiled in water bath for 10 min. Then it was cooled and centrifuged at 3000 rpm for 10 min and the supernatant was collected. This process was repeated thrice, to make up 5 volumes of the sample taken. The supernatant was finally stored at -30°C.(Khora, 1991). The extract is given at dose of (1 ml /100gm per b. w.) according to (Saoudi *et al.*, 2008).

Preparation of *Nigella sativa* extract:

Nigella sativa (black cumin) seeds were purchased from the local market in Qena Governorate, Egypt. *N. sativa* prepared according to the method of Kushwah *et al.* (2014). Briefly, Seeds were grounded to powder with the help of mortar and pestle and 150 of powder was soaked in 250 mL of 99% of ethanol in closed container at room temperature for 7 days with periodic stirring with a sterile glass rod. After 7 days it was filtered with wittman filter paper No1 and extract was concentrated by rotary vaccum evaporator and kept in desiccator for complete removal of solvent. The extract so obtained was stored at 4° c till further use at dose of (Kushwah *et al.*, 2014).

Vitamin E:

Vitamin E was purchased from pharmacy in the form of soft gelatin capsules, each containing 400 mg of vitamin E (Cairo Pharm. & Chem. Ind. Co., Cairo, Egypt). The dose 100 mg/kg BW of Vitamin E was used because other previous studies showed that this dose was effective against the toxicity of pesticides (fenvalerate) and carbon tetrachloride (El-Demerdash *et al.*, 2004).

Experimental design

Fifty rats were randomly divided into five groups (N= 10) as the following: Group 1 received saline solution and served as a normal group. Group 2: injected intraperitoneally with liver extract of the *L. spadiceus* in dose of (1 ml/100 gm, b. w.) for successive 10 days and served as a control group. Group 3: The rats were injected intraperitoneal with liver extract of *L. spadiceus* (1 ml/100 gm, b. w) daily for 10 days and treated with oral administration of *N. sativa* extract (500 mg/kg per body weight) daily for successive 30 days. Group 4: the rats were injected intraperitoneal with liver extract of *L. spadiceus* (1 ml/100 gm, b. w.) daily for 10 days, and treated with oral administration of vitamin E (100 mg/kg per body weight) daily for 30 days. Group 5: the rats were intraperitoneally injected with liver extract of puffer fish *L. spadiceus* (1 ml/100 gm, b. w.) daily for 10 days and then received both of *N. sativa* extract (500 mg/kg, body weight) and vitamin E (100 mg/kg per body weight) orally for 30 consecutive days. All rats were humanely euthanized 24 h after the last application and blood samples were collected for hematological, biochemical and histopathological examination.

Hemtological Analysis

At the end of experiment, all animals were sacrificed and the blood was taken in EDTA containing tubes from every animal. This blood was used for the examination of complete blood picture (platelets count, red blood cells count (RBCs),

leukocytes count (WBCs), total hemoglobin (Hb) and hematocrit assays (PCV) which done by Automated Hematology Analyzer (Diagon LTd - D cell 60).

Biochemical Analysis:

a-Serum indices of hepatotoxicity:

Determination of alanine aminotransferase (ALT), Aspartate aminotransferase (AST), alkaline phosphatase (ALP), total protein and albumin was performed according to the manufacturer's protocol of reagent kits purchased from spectrum Diagnostics, Egypt.

b-Serum indices of renal toxicity:

Determination of serum creatinine, Blood Urea Nitrogen (BUN) and uric acid was performed according to the manufacturer's protocol of reagent kits purchased from (Bio diagnostics, Egypt). Uric acid and Creatinine were brought from spectrum Diagnostics. Egypt. While urea kits were brought from Diamond, Egypt).

Histopathological examinations:

Following complete necropsy of the experimental male rats, small fresh specimens from testes, liver and kidney were collected and rapidly fixed in 10% formalin solution for at least 24 h. After that, these specimens were processed through the conventional paraffin embedding techniques (dehydration in ascending grades of ethyl alcohol, clearing in different changes of xylene and embedding in different changes of melted paraffin wax at 60°C). Paraffin blocks were cut by microtome in to 5 microns, thick sections which were stained by Hematoxylin and Eosin (H&E), according to the method described by Culling, (1983).

Statistical analysis:

The results are expressed as mean \pm S.E. The means comparisons were made by using one-way analysis of variance (ANOVA) using Graph Pad Prism 03n software, where appropriate. Statistical significance was set at $p < 0.05$.

RESULTS

Effect on hematological parameters:

Rats injected with Tetradoxin (TTX) extracted from liver of *L. spadiceus* resulted in a significant decrease in RBCs count, Hb concentration and PCV value at ($p < 0.05$) when compared with the normal animals. On the other hand, WBCs and PLT counts were significantly increased. These results were recorded in Figure (1). Daily treatment with *N. sativa*, Vitamin E and *N. sativa* plus vitamin E for 30 days showed an improvement increase at ($p < 0.05$) in RBCs count, Hb concentration and PCV value when compared with control, while WBCs and PLT count recorded a significant decrease when compared with normal animals.

On the other hand, RBCs count, PCV % and Hb conc. were significantly increased and highly significant reduced in WBCs and platelets counts in group 3, 4, 5 when compared to control group.

Effect on Biochemical parameters:

Liver function

As showed in Figure (2), rats treated with TTX induced a significant increase at ($p < 0.05$) in serum ALT, AST and ALP activities as compared with the corresponding normal values. It induced also a significant decrease at ($p < 0.05$) in serum Albumin level and total protein when compared with normal level. On the other hand, oral administration of *N. sativa* treatments for 30 days, there were a significant decrease at ($p < 0.05$) in serum ALT, AST and ALP activities when

compared with control animals and there was a significant increase at ($p < 0.05$) in albumin and total protein level as compared with control animals.

Vitamin E and *N. sativa* plus vitamin E treatment for 30 days showed a significant decrease at ($p < 0.05$) in serum ALT, AST and ALP activities comparing with control animals, this decrease was showed marked improvements nearly reachable to normal levels. While serum albumin level and total protein showed a significant increased comparing with control animals level as well as, this increase in albumin and total protein level was nearly reachable to normal levels.

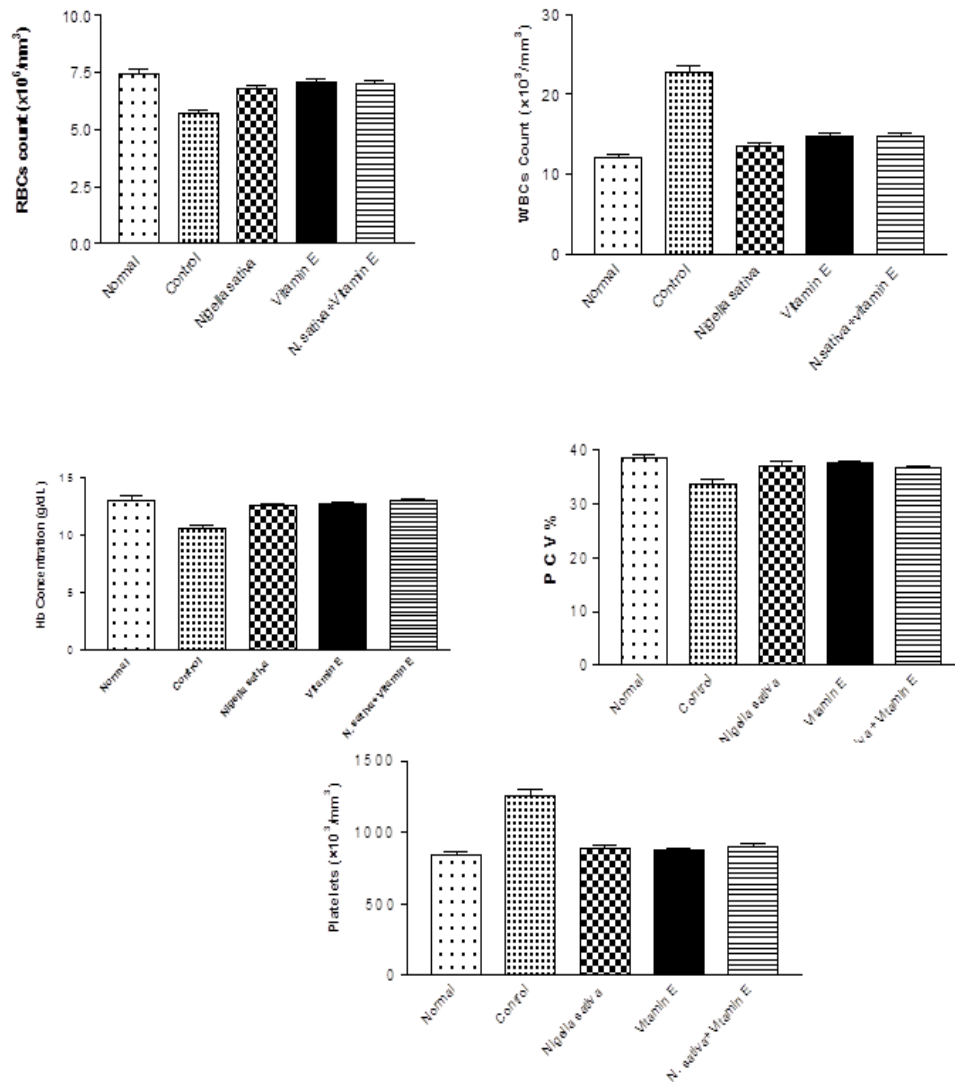


Figure (1): Effect of oral administration of *Nigella sativa* extract (500 mg/kg body weight), Vitamin E (100mg/kg body weight) and *Nigella sativa* + Vitamin E daily for 30 days after i. p. injection with *Lagocephalus spadiceus* liver extract (1 ml/100 g body weight) daily for 10 days on some hematological parameters of male Albino rats

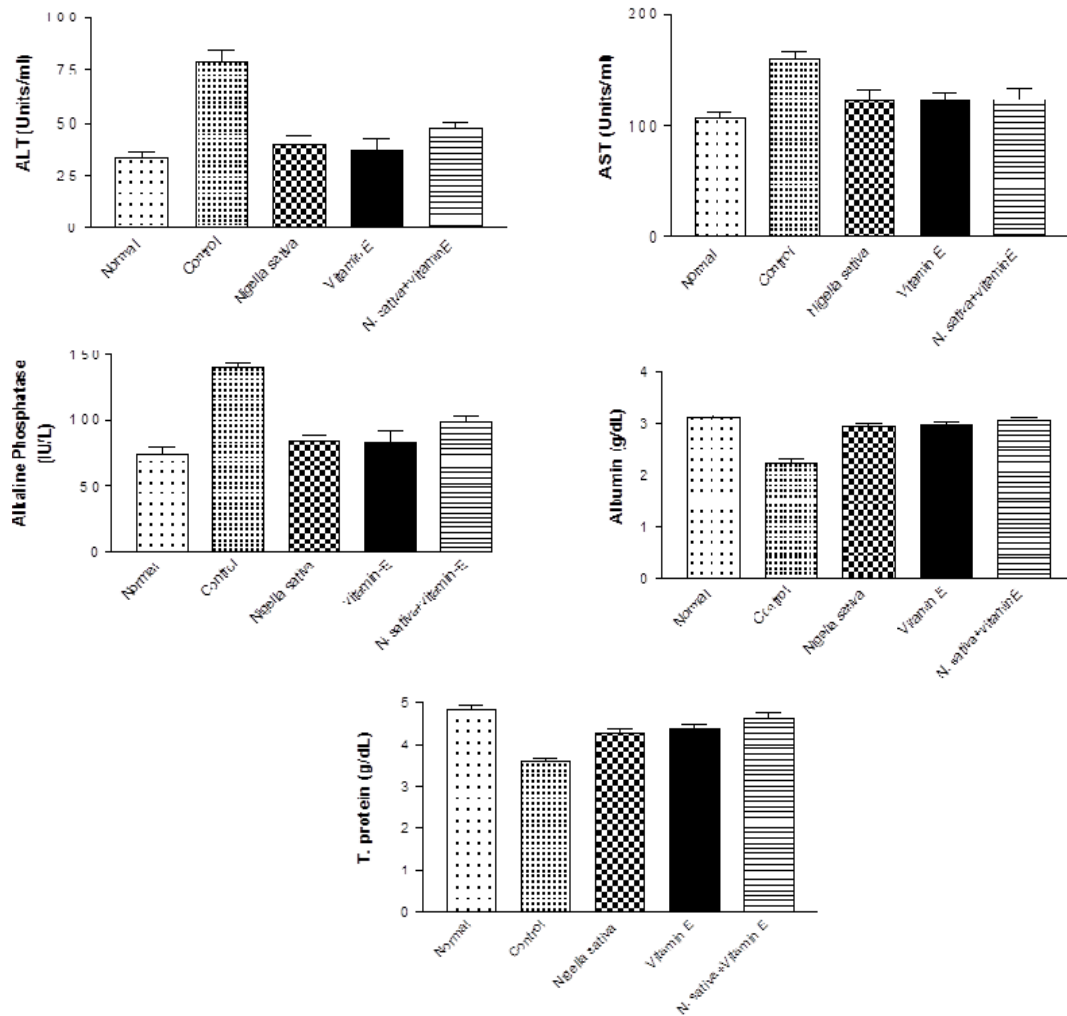


Figure (2): Effect of oral administration of *Nigella sativa* extract (500 mg/kg body weight), Vitamin E (100mg/kg body weight) and *Nigella sativa* + Vitamin E daily for 30 days after i. p. injection with *Lagocephalus spadiceus* liver extract (1 ml/100 g body weight) daily for 10 days on some level of liver function in blood of male Albino rats

Kidney function

As shown in Figure (3), creatinine, urea and Uric acid in serum of the control groups showed a significant increase at ($p < 0.05$) when compared with the normal group. Treated groups of *N. sativa*, Vitamin E and *N. sativa* plus vitamin E recorded a remarkable improvement, comparing with normal animals and showed a significant decreases at ($p < 0.05$) in serum creatinine, urea and uric acid levels comparing to control animals

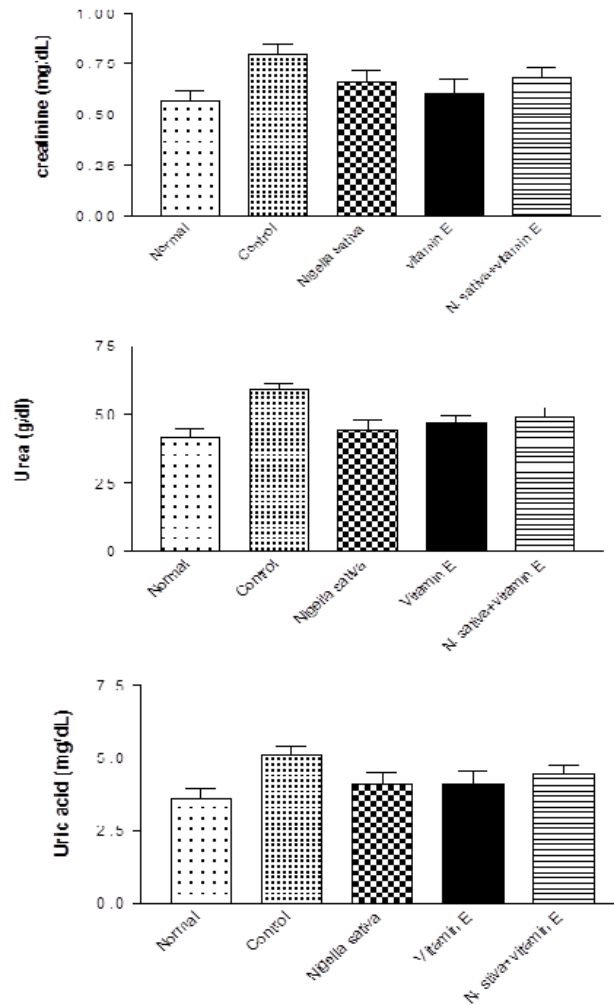


Figure (3): Effect of oral administration of *Nigella sativa* extract (500 mg/kg body weight), Vitamin E (100mg/kg body weight) and *Nigella sativa* + Vitamin E daily for 30 days after i.p. injection with *Lagocephalus spadiceus* liver extract (1 ml/100 g body weight) daily for 10 days on kidney function in blood of male Albino rats.

Histopathological finding:

Liver and kidney are very important and sensitive organs in the body. Exposure of the liver to TTX induced necrosis in the hepatocytes around the central vein associated with presence of some necrosed cells in the lumen of the central vein beside blood sinusoid dilation. Treatment of exposed animals with *N. sativa* extract and Vitamin E in group 3 and 4, induced relive to the hepatic injury characterized by mild degree of necrosis in the hepatocytes. In advance, administration treatment with a mixture of *N. sativa* extract and Vitamin E (group 5) induced complete relive to the liver injury confirmed by appearance of the hepatocytes near to the healthy cells. In kidneys of Group 2 severe necrosis in the glomerular epithelium with inflammatory cells infiltration besides narrowing to Bowman' s space was observed after exposure to TTX toxin. kidneys of groups 3 and 4 showing degeneration in the renal tubular epithelium characterized by casts formation with dilatation in some renal tubules after *N. sativa* extract and Vitamin E administration. Administration to combination of *N. sativa* extract and Vitamin E in group 5 induced minimal degree of necrosis and recovery to the tubular epithelium. These results recorded in figures 4&5.

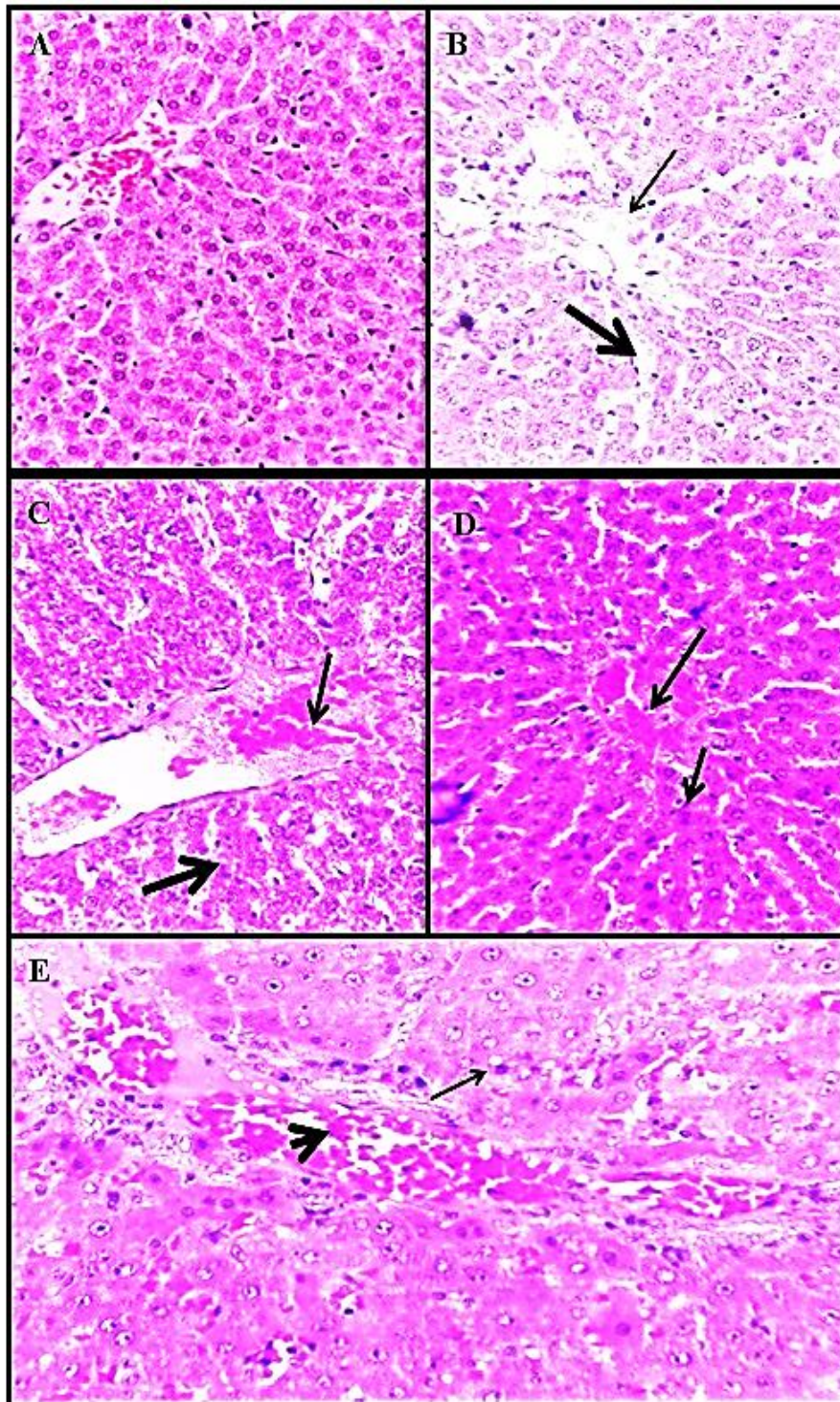


Figure (4): Photomicrograph of liver (A,B,C,D and E) group 1,2,3,4, and 5 respectively showing necrosis in the hepatocytes around the central vein B with minimal degree of necrosis in the hepatocytes C. some hepatocytes inside the lobules appeared with normal architecture in most of rats D. hepatocytes appear similar to healthy cells E (H & E. x 400).

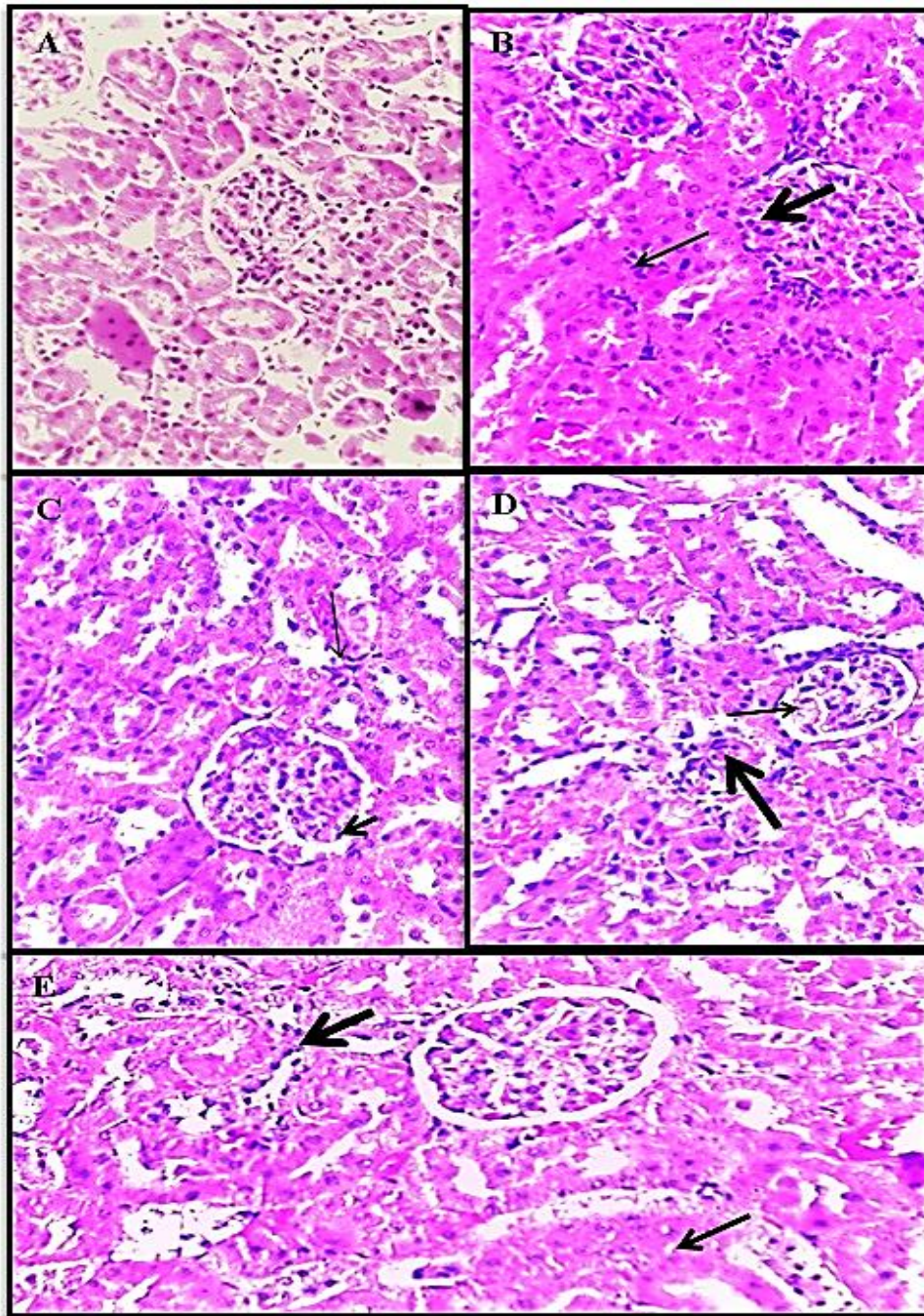


Figure (5): Photomicrograph of liver (A,B,C,D and E) group 1,2,3,4,and 5 respectively showing severe necrosis in glomerular epithelium with inflammatory cells infiltration B. Degeneration in the renal tubular epitheliums was observed in group3(C). In group 4 (D) kidneys showing mild degree of necrosis with dilatation in some renal tubules. Kidneys of group5 (E) showing minimal degree of necrosis (H & E. x400).

DISCUSSION

In our study we observed that, *L. spadiceus* liver extract had a toxic effect on hematological parameters causing highly significant decrease RBCs count, PCV % and Hb conc., while it induce highly significant increase in WBCs and Platelets counts. These findings agree with those of (Saoudi *et al.*, 2008 and Niharika Mandal *et al.*, 2013).

The decreases in RBCs, Hb conc., and PCV% resulted from direct effect of toxin on erythrocytes causing oxidative damage to membrane lipids. Lipid peroxidation causes membrane depolarization and causes the loss of plasmatic membrane integrity (Bartosz, 2003). Production of lipid peroxides also lead to the hemolysis of RBCs, this might be the reason for the reduction in RBCs count, PCV % and Hb level. Also, the increasing in WBCs and PLTs may be attributed the defensive mechanism of immune system. These findings agreed with those of (Patrick-Iwuanyanwu *et al.*, 2007).

In agreement with Meral *et al.* (2004) and Demir *et al.* (2006), Oral administration of *N. sativa* extract induced recovery in hematological parameters. This plant enhanced these parameters via lipid peroxidation reduction.

The obtained results showed that, vitamin E make treatment in hematological parameters, these treatment can attributed to α -Tocopherol is more lipophilic and a potent antioxidant. It protects cellular components against peroxidative damage by a free-radical scavenging mechanism. (Mohri *et al.*, 2005 and Niki, 2014).

In this study, the liver extract of *L. spadiceus* induced increase in AST, ALT and ALP is due to the damage of hepatocytes results in the leakage of these enzymes into systemic circulation, the present results are in accordance with other studies (Kew, 2000 and Hyun *et al.*, 2010). It was also found that the rats injected with *L. spadiceus* liver extract showed significant decrease in Albumin and T. proteins, these results due to pathological alteration in liver that lead to hepatic dysfunction and decreased protein synthesis (Saleh, 2011).

In the present study *N. sativa* extract treated animals showed enhancement in the liver functions parameters, this enhancement due to hepatoprotective effect of *N. sativa* which may be successful to decrease liver damage induced by liver extract of *L. spadiceus*. These results are consistent with other studies (Danladi *et al.*, 2013 and Hamza and Al-Harbi, 2015).

Our results reported that vitamin E protects critical cellular structures against damage caused by oxygen-free radicals and it inhibits lipid peroxidation of membrane by scavenging lipid peroxy radicals that decrease the oxidative stress in liver leading to improve in liver functions (Hashem *et al.*, 2013).

The recorded results of the present study indicated that in injection with liver extract of *L. spadiceus* induced elevation in creatinine, urea and uric acid, the increase in these previous parameters may be due to a direct effect of these toxins on the kidney, which in turn would cause uncontrolled cellular permeability of the glomeruli leading to decreased glomerular filtration rate and increase in these parameters in blood (Saoudi *et al.*, 2010).

The results obtained in the present study showed that, kidney function was improved as indicated by reduction in serum Creatinine, Urea and Uric acid levels after oral administration of *N. sativa* may be the possible mechanism of anti-inflammatory action of thymoquinone which has a therapeutic potential in treatment or prevention of inflammatory diseases in kidneys (Tembhurne *et al.*, 2011).

In vitamin E treated animals showed healing in kidneys function by decreasing the concentration of creatinine, urea and uric acid, these results in accordance with (Bansal *et al.*, 2005).

Intraperitoneal injection of the *L. spadiceus* liver extract induced hepatotoxicity. The hepatotoxicity was manifested by many histological features includes necrosis in the hepatocytes associated with vasculitis and dilatation in the blood sinusoids. The changes in the hepatic cells and blood vessels were attributed to the direct effect of the toxins the cells structures or due to the free radicals which caused structural integrity damage of the liver cell membrane and hence a leakage of the cellular enzymes in to the blood (Patel *et al.*, 2010).

Oral administration of *N. sativa* and vitamin E induced restoration to the liver tissue to the healthy. The tissues recovery of the liver suggested due to the antioxidant activity of herbal plant which possessed radical scavenging and antioxidant (Badary *et al.*, 2003& 2007).

For the renal toxicity intra peritoneal injection of the TTX induced necrosis in the glomerular endothelial cells and renal tubules epithelium. Moreover, hemorrhage was noticed in between the renal tubules. The histopathological changes in the kidney following injection of *L. spadiceus* liver extract were due to the direct effect of the toxins on the renal epithelium (Saoudi *et al.*, 2010 and Nejla *et al.*, 2010).

Oral administration of *N. sativa* and vitamin E caused recovery in the renal tissues and cells appear near to healthy. This restoration and recovery may be due to the multi-beneficial properties of *N. Sativa* extracts plus vitamin E such as antioxidant (Fouda *et al.*, 2008 and Alenzi *et al.*, 2013), anti-inflammatory (Hajhashemi *et al.*, 2004).

Conclusion:

From our study, we concluded that, the injection of *L. spadiceus* liver extract induced hematological, biochemical and pathological changes. Also we concluded that *Nigella sativa* extract and Vitamin E could be used as a powerful antioxidant against the side effects of *L. spadiceus* liver extract.

REFERENCES

- Alenzi, F. Q.; AlsakranAltamimi, M. A.; Kujan, O.; Tarakji, B.; Tamimi, W. *et al.* (2013): Antioxidant Properties of *Nigella sativa*. *J. Mol. Genet. Med.*, 7: 77.
- Al-Saleh, I. A.; Billedo, G. and El-Doush, I. I. (2006): Levels of selenium, dl- α -tocopherol, dl- γ -tocopherol, all-trans-retinol, thymoquinone and thymol in different brands of *Nigella sativa* seeds. *J. Food Compost. Anal.*, 19(2-3): 167–175.
- Asakawa, M.; Toyoshima, T.; Shida, Y.; Noguchi, T. and Miyazawa, K. (2000): Paralytic toxins in a ribbon worm *Cephalothrix* species (Nemertean) adherent to cultured oysters in Hiroshima Bay, Hiroshima Prefecture, Japan. *Toxicol.*, 38(6): 763–773.
- Badary, O. A.; Abd-Ellah, M.F.; El-Mahdy, M. A.; Salama, S. A. and Hamada, F. M. (2007): Anticlastogenic activity of thymoquinone against benzo(a)pyrene in mice. *Food Chem. Toxicol.*, 45(1):88–92.
- Badary, O. A.; Taha, R. A.; Gamal El-Din, A.M. and Abdel-Wahab, M. H. (2003): Thymoquinone is a potent superoxide anion scavenger. *Drug. Chem. Toxicol.*, 26: 87–98.
- Bane, V.; Lehane, M.; Dikshit, M.; O'Riordan, A. and Furey, A. (2014): Tetrodotoxin: Chemistry, toxicity, source, distribution and detection. *Toxins (Basel)*, 6(2): 693–755.

- Bansal, A. K.; Bansal, M.; Soni, G. and bhatnagar, D. (2005): Protective role of vitamin E-pretreatment on N-nitrosodiethylamine induced oxidative stress in rat liver. *Chem. Biol. Interact.*, 156: 101-111.
- Bartosz, G. (2003): The other face of oxygen. The free radicals in environment (in Polish).
- Boskabady, M. H.; Keyhanmanesh, R.; Khameneh, S.; Doostdar, Y. and Khakzad, M. R. (2011): Potential immunomodulation effect of the extract of *Nigella sativa* on ovalbumin sensitized guinea pigs. *J. Zhejiang. Univ. Sci. B.*, 12(3): 201-209.
- Culling, C. F. (1983): Handbook of histological and histochemical techniques. 3rd ed., butterworth, London, boston.
- Danloadi, J. ; Abdusalam, A. ;Timbuak, J. A. ; Ahmad, S. A.; Mairiga, A. A. and Dahirn, A. U.(2013): Hepatoprotective effect of black seed *Nigella sativa* oil on tetrachloride (CCL4) induced liver toxicity in adult wistar rats. *J. Dent. Med. Sci.*, 4(3):56-62.
- Demir, H. K.; Coskun, O.; Uz, Y. H.; Koe, A. and Yildiz, A. (2006): Effect of black cumin (*Nigella sativa*) on heart rate, some hematological values, and pancreatic beta-cell damage in cadmium-treated rats. *Biol. Trace. Elem. Res.*, 110(2):151-62.
- Dollah, M. A.; Parhizkar, S.; Latiff, L.A. and Bin Hassan, M. H. (2013): Toxicity effect of *Nigella sativa* on the liver function of rats. *Adv. Pharm. Bull.*, 3(1):97-102.
- El-Demerdash, F. M.; Yousef, M. I. Kedwany, F. S. and Baghdadi, H. H. (2004): Cadmium-induced changes in lipid peroxidation, blood hematology, biochemical parameters and semen quality of male rats: protective role of vitamin E and b-carotene. *Food Chem. Toxicol.*, 42(10): 1563–1571.
- Fouda, A. M.; Daba, M. H.; Dahab, G. M. and Sharaf El-Din, O. A. (2008): Thymoquinone ameliorates renal oxidative damage and proliferative response induced by mercuric chloride in rats. *Basic Clin. Pharmacol. Toxicol.*, 103(2): 109-118.
- Gholamnezhad, Z.; Havakhah, S. and Boskabady, M. H. (2016): Preclinical and clinical effects of *Nigella sativa* and its constituent, thymoquinone: A review. *J Ethnopharmacol.*, 190: 372–386.
- Gholamnezhad, Z.; Keyhanmanesh, R. and Boskabady, M. H. (2015): Anti-inflammatory, antioxidant, and immunomodulatory aspects of *Nigella sativa* for its preventive and bronchodilatory effects on obstructive respiratory diseases: A review of basic and clinical evidence. *J. Funct. Food*, 17:910-27.
- Hajhashemi, V.; Ghannadi, A. and Jafarabadi, H. (2004): Black cumin seed essential oil as a potential analgesic and anti-inflammatory. *Phytother. Res.*, 18(3):195-199.
- Hamza, R. Z. and Al-Harbi, M. S. (2015): Amelioration of paracetamol hepatotoxicity and oxidative stress on mice liver with silymarin and *Nigella sativa* extract supplements. *Pac. J. Trop. Biomed.*, 5(7): 521–531.
- Hashem, N. M.; AbdEl-Hady, A. and Hassan, O.(2013): Effect of vitamin E or propolis supplementation on semen quality, oxidative status and hemato-biochemical changes of rabbit bucks during hot season. *Livestock. Sci.*, 157(2-3): 520-526.
- Homaira, N.; Rahman, M.; Luby, S. P.; Rahman, M.; Haider, M. S.; Faruque, L. I.; Khan, D.; Parveen, S. and Gurley, E. S. (2010): Multiple outbreaks of puffer fish intoxication in Bangladesh, 2008. *Am. J. Trop. Med. Hyg.*, 83(2):440-444.

- Hwang, D. F. and Noguchi, T. (2007): Tetrodotoxin Poisoning. *Adv. Food Nutr. Res.*, 52: 141-236.
- Hyun, P. S.; Kannampalli, P.; MiHee, Ch.; Kyong-Cheol, K. and Hae-Jun, P. (2010): Hesperidin and Curdlan treatment ameliorate γ - radiation induced cellular damage and oxidative stress in the liver of Sprague rats. *Dawley*, 1(3): 165-177.
- Kew, M. C. (2000): Serum aminotransferase concentration as evidence of hepatocellular damage. *Lancet.*, 355(9204):591-592.
- Khan, M. A. and Afzal, M. (2016): Chemical composition of *Nigella sativa*. *Inflammopharmacology*, 24:67-79.
- Khazdair, M. R. (2015): The Protective Effects of *Nigella sativa* and Its Constituents on Induced Neurotoxicity. *J. Toxicol.*, 2015: 1-7.
- Khora, S. S.; Isa, J. and Yasumoto, T. (1991): Toxicity of puffers from Okinawa, Japan. *Nippon. Suisan. Gakkaishi.*, 57(1): 163–167.
- Kushwah, D. S. (2014): Comparison of ameliorative of essential oil and ethanolic extract of *Nigella sativa* seed in acetaminophen induced liver damage. *Int .J. Pharm. Bio. Sci.*, 5(3): 466 – 471.
- Lago, J.; Rodríguez, L.P.; Blanco, L.; Vieites, J.M., et al. (2015): Tetrodotoxin, an extremely potent marine neurotoxin: distribution, toxicity, origin and therapeutical uses. *Mar. Drugs.*, 13: 6384–6406.
- Lin, H.; Nagashima, Y.; Jiang, P.; Qin, X.; Lu, Y. and Zhang, C. (2012): Screening for toxicity and resistance to paralytic shellfish toxin of shore crabs inhabiting at Leizhou peninsula, China. *Mar. Environ. Res.*, 78: 48–52.
- Lin, S. J. and Hwang, D. F. (2001): Possible source of tetrodotoxin in the starfish *Astropecten scoparius*. *Toxicon.*, 39(4): 573–579.
- Luo, X.; Yu, R. C.; Wang, X. J.; Zhou, M. J. (2012): Toxin composition and toxicity dynamics of marine gastropod *Nassarius* spp. collected from Lianyungang, China. *Food Addit. Contam. Part A. Chem. Anal. Control Expo. Risk. Assess.*, 29(1):117-127.
- McNabb, P.; Selwood, A.I.; Munday, R.; Wood, S.A.; Taylor, D.I.; MacKenzie, L.A.; van Ginkel, R.; Rhodes, L.L.; Cornelisen, C.; Heasman, K.; Holland, P. T. and King, C. (2010): Detection of tetrodotoxin from the grey side-gilled sea slug - *Pleurobranchaea maculata*, and associated dog neurotoxicosis on beaches adjacent to the Hauraki Gulf, Auckland, New Zealand. *Toxicon.*, 56(3): 466–473.
- Mebs, D. and Yotsu-Yamashita, M. (2012): Tetrodotoxin in North-American newts. *Toxicon.*, 60: 1–120.
- Meral, I.; Donmez, N.; Baydas , B.; Belge, F. and Kanter, M. (2004): Effect of *Nigella sativa* L. on hrarth rate and some haematological values of alloxan-induced diabetic rabbits. *Scand. J. Lab. Anim. Sci.*, 31(1): 49-53.
- Mohri, M.; Seifi, H. A. and Khodadadi, J. (2005): Effects of preweaning parenteral supplementation of vitamin E and selenium on hematology, serum proteins, and weight gain in dairy calves. *Comp. Clin. Pathol.*, 14(3): 149–154
- Negi, A. S.; Kumar, J. K.; Luqman, S.; Shanker, K.; Gupta, M. M. and Khanuja, S. P. (2007): Recent advances in plant hepatoprotectives: a chemical and biological profile of some important leads. *Med. Res. Rev.*, 28 (5): 746-772.
- Nejla, S.; Mediha, S.; Ibtissem, B. A.; Tahia, B. and Najiba, Z. (2010): Protective effects of Selenium (Se) on Chromium (VI) induced nephrotoxicity in adult rats. *Ecotoxicol. Environ. Saft.*, 73: 671-678.

- Niharika, M. and Khora, S. S. (2013): Ameliorative action of aqueous extract of *Acalypha indica* against puffer fish *Lagocephalus lunaris* induced toxicity. *Int. J. Drug Dev. & Res.*, 5(2): 257-271.
- Niki, E. (2014): Role of vitamin E as a lipid-soluble peroxy radical scavenger: in vitro and in vivo evidence. *Free Radic. Biol. Med.*, 66:3-12.
- Noguchi, T. and Arakawa, O. (2008): Tetrodotoxin- distribution and accumulation in aquatic organisms, and cases of Human intoxication. *Mar. Drugs.*, 6(2): 220-242.
- Pal, S. and Bhattacharjee, S. (2014): Additive protective effects of selenium and vitamin E against Arsenic induced lipidemic and cardiotoxic effects in mice. *Int. J. Pharm. Pharm. Sci.*, 6(5): 406-413.
- Patel, B. A.; Patel, J. D.; Raval, B. P. and Gandhi, T. R. (2010): The protective activity of Saccharum officinarum against CCl₄ induced Hepatotoxicity in rats. *Int. J. Pharm. Res.*, 2(3): 5-8.
- Patrick-Iwuanyanwu, K. C.; Wegwu, M. O. and Ayalogu, E. O. (2007): Prevention of CCl₄-induced liver damage by ginger, garlic and vitamin E. *Pak. J. Bio. Sci.*, 10 (4): 617-621.
- Pires, O.R., Jr.; Sebben, A.; Schwartz, E.F.; Bloch, C., Jr.; Morales, R.A.V. and Schwartz, C.A. (2003): The occurrence of 11-oxotetrodotoxin, a rare tetrodotoxin analogue, in the brachycephalidae frog *Brachycephalus ephippium*. *Toxicon.*, 42(5): 563–566.
- Pourbakhsh, H.; Taghiabadi, E.; Abnou, K.; Hariri, A. T.; Hosseini, S. M. and Hosseinzadeh, H. (2014): Effect of *Nigella sativa* fixed oil on ethanol toxicity in rats. *Iran. J. Basic. Med. Sci.*, 17(12): 1020.
- Saleem, U.; Ahmad, B.; Rehman, K.; Mahmood, S.; Alam, M. and Erum, A. (2012): Nephro-protective effect of vitamin C and *Nigella sativa* oil on gentamicin associated nephrotoxicity in rabbits. *Pak J Pharm Sci*, 25(4): 727-730.
- Saleh, E. S. A. (2011): Hematological and Biochemical Studies on the Effect of Some Natural Antioxidants Pre-Injection in Irradiated Rats. Ph.D. Thesis, Dept. of Biochem. Fac. of Agric. Benha Univ. Egypt.
- Saoudi, M.; Abdelmouleh, A.; Jamoussi, K.; Kammoun, A. and El Feki A. (2008): Hematological toxicity associated with tissue extract from poisonous fish *Lagocephalus lagocephalus*-influence on erythrocyte function in wistar rats. *J. Food Sci.*, 73(7): 155-159.
- Saoudi, M.; Allagui, M. S.; Abdelmouleh, A.; Jamoussi, K. and El Feki, A. (2010): Protective effect of poisoning in Bangladesh. *J. Nat. Toxins.*, 9: 319-326.
- Tembhurne, S. V.; Feroz, S.; More, B. H. and Sakarkar, D. M. (2011): A review on therapeutic potential of *Nigella sativa* (kalonji) seeds. *J. Med. Plants Res.*, 8(3): 167–177.
- van Apeldoorn, M. E.; van Egmond, H. P.; Speijers, G. J. A. and Bakker, G. J. I. (2007): Toxins of cyanobacteria. *Mol. Nutri. Food Res.*, 51 (1): 7–60.
- Williams, B. L.; Stark, M. R. and Caldwell, R. L. (2012): Microdistribution of tetrodotoxin in two species of blue-ringed octopuses (*Hapalochlaena lunulata* and *Hapalochlaena fasciata*) detected by fluorescent immunolabeling. *Toxicon*, 60(7): 1307–1313.
- Williams, B.L. and Caldwell, R.L. (2009): Intra-organismal distribution of tetrodotoxin in two species of blue-ringed octopuses (*Hapalochlaena fasciata* and *H. lunulata*). *Toxicon*, 54(3): 345–353.
- Wood, S.; Casas, M.; Taylor, D.; McNabb, P.; Salvitti, L.; Ogilvie, S. and Cary, S.C. (2012): Depuration of tetrodotoxin and changes in bacterial communities in

- Pleurobranchea maculata adults and egg masses maintained in captivity. J. Chem. Ecol., 38(11): 1342–1350.
- Yang, G.; Xu, J.; Liang, S.; Ren, D.; Yan, X. and Bao, B. (2010): A novel TTX-producing *Aeromonas* isolated from the ovary of *Takifugu obscurus*. *Toxicon*, 56(3): 324–329.
- Yu, V.C.; Yu, P.H.; Ho, K.C. and Lee, F.W. (2011): Isolation and identification of a new tetrodotoxin-producing bacterial species, *Raoultella terrigena*, from Hong Kong marine puffer fish *Takifugu niphobles*. *Mar. Drugs*, 9(11): 2384–2396.

ARABIC SUMMERY

التأثير التحسيني لحبة البركة وفيتامين "هـ" علي السمية المستحدثة بواسطة المستخلص الكبدي لسماك الأرنب (*Lagocephalus spadiceus*) في ذكور الفئران البيضاء

محمد محمود علي سالماني^١، نجلاء رشاد عطا الله قاسم^١، شيماء ضاحي شحات محارب^١ و عاطف محمد خليل^٢

^١، قسم علم الحيوان – كلية العلوم – جامعة جنوب الوادي
^٢ قسم الباثولوجيا والباثولوجيا الإكلينيكية – كلية الطب البيطري- جامعة جنوب الوادي

هذه الدراسة تهدف إلي دراسة الأثر العلاجي لبعض مضادات الأكسدة مثل حبة البركة وفيتامين "هـ" علي الإضطرابات الناجمة من المستخلص الكبدي لسماك الأرنب (*Lagocephalus spadiceus*) علي المكونات الخلوية للدم والقياسات البيوكيميائية و الهستوباثولوجية في ذكور الفئران البيضاء. قد تم تصميم الدراسة علي خمس مجموعات من ذكور الفئران البيضاء (١٠ فأر لكل مجموعة). المجموعة ١: تم حقنها بمحلول ملحي في الغشاء البريتوني واعتبرت كمجموعة طبيعية. المجموعة ٢: حقنت في الغشاء البريتوني بالمستخلص الكبدي لسماك الأرنب (١ مل/ ١٠٠ جم من وزن الجسم) لمدة عشرة أيام واعتبرت كمجموعة ضابطة. أما المجموعة ٣: تم إعطاؤها مستخلص بذور حبة البركة من خلال الفم بجرعة (٥٠٠ مجم/ كجم من وزن الجسم) لمدة ٣٠ يوماً بعد حقنها لمدة عشر أيام بالمستخلص الكبدي لسماك الأرنب. المجموعة ٤: تم معالجة الفئران بفيتامين "هـ" من خلال الفم (١٠٠ مجم/ كجم من وزن الجسم) لمدة ٣٠ يوماً بعد حقنها لمدة عشرة أيام بالمستخلص الكبدي لسماك الأرنب. المجموعة ٥: تم إعطاؤها مستخلص بذور حبة البركة + فيتامين "هـ" لمدة ٣٠ يوماً بعد حقنها بالمستخلص الكبدي لسماك الأرنب لمدة عشرة أيام. من النتائج يتضح لنا أن المجموعة الضابطة أظهرت نقص ملحوظ في عدد كريات الدم الحمراء وتركيز الهيموجلوبين وحجم خلايا الدم الحمراء المتجمعة (PCV) مع ارتفاع في عدد كريات الدم البيضاء والصفائح الدموية. وكذلك أدي إلي ارتفاع في أنشطة كلا من (ALT, AST & ALP) مع ارتفاع في تركيز كلا من الكرياتينين والبولينا وحمض البوليك، مع نقص في مستوي الألبومين والبروتين الكلي بالإضافة الي حدوث تركز في كلا من خلايا الكبد والكلي. ومن تلك النتائج نستطيع أن نستنتج أن كلا من حبة البركة و فيتامين "هـ" لهم دور تحسيني ضد تلف الخلايا الناتج من الشوارد الحرة المستحدثة بواسطة المستخلص الكبدي لسماك الأرنب.